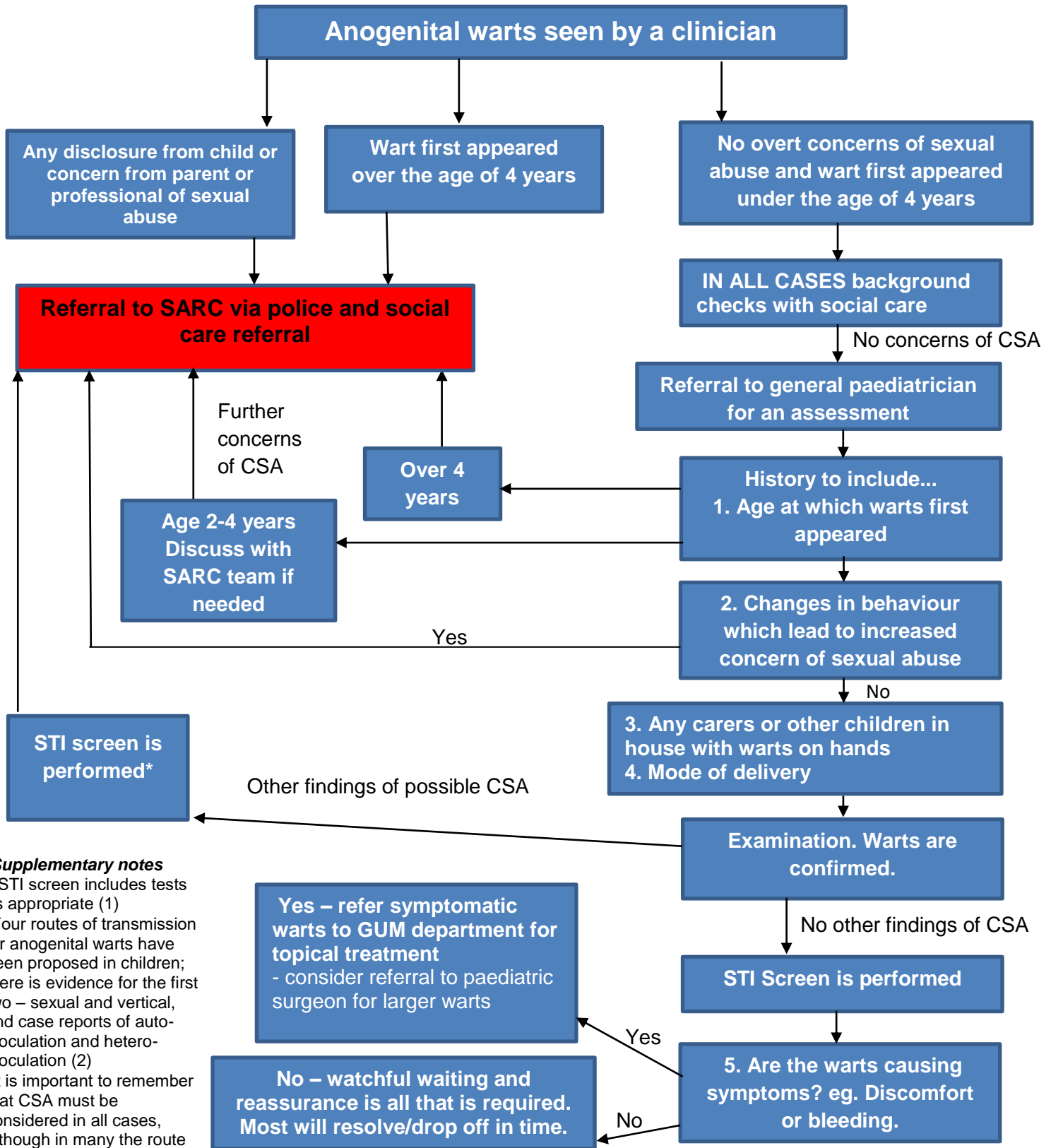




# Anogenital warts in prepubertal children: Referral and Management Guidelines



**Supplementary notes**

- \*STI screen includes tests as appropriate (1)
- Four routes of transmission for anogenital warts have been proposed in children; there is evidence for the first two – sexual and vertical, and case reports of auto-inoculation and hetero-inoculation (2)
- It is important to remember that CSA must be considered in all cases, although in many the route of transmission may ultimately be unclear